

Review

Delayed Complications After Cochlear Implantation

Bradford Terry, MD; Rachel E. Kelt, MD; Anita Jeyakumar, MD, MS

IMPORTANCE Surgeons should understand the potential long-term complications in patients who undergo cochlear implantation (CI) and should be able to facilitate counseling.

OBJECTIVES To review the delayed complications after CI and some of the management plans used to treat these complications.

EVIDENCE ACQUISITION The PubMed and OVID databases were searched for articles published from January 1, 2003, through December 31, 2013, using the search terms *cochlear implant and complications*. Seven hundred sixty-six articles were identified and searched for reports of delayed complications (≥ 3 days after surgery). Exclusion criteria consisted of a language other than English, no long-term follow-up or report of delayed complications, small case series with fewer than 10 patients, and CI in patients with cochlear malformations. Additional articles were identified with specific search criteria consisting of *cochlear implant* combined with *mastoiditis*, *meningitis complication*, *otitis media*, *hematoma*, *cholesteatoma*, and *facial nerve injury*. Data were collected from January 1 through April 1, 2014, and analyzed from April 30 to May 3, 2014.

FINDINGS A total of 88 individual articles were analyzed for this study. These articles included a total of 22 842 patients. Of 8519 patients with data in regard to sex, 4319 (50.7%) were male. The patients' ages ranged from 0.2 to 94.9 years, with a mean age of 19.0 years. The duration of follow-up ranged from 1 month to 17 years. The total number of delayed complications was 1302 (5.7%), with vestibular complications (181 of 4655 patients [3.9%]) being the most common; device failure (507 of 14 704 patients [3.4%]), the second most common; and taste problems (22 of 776 patients [2.8%]), the third most common. Less common complications included cholesteatoma (40 of 8579 patients [0.5%]) and facial nerve palsy (31 of 4785 patients [0.6%]).

CONCLUSIONS AND RELEVANCE Cochlear implantation continues to be a reliable and safe procedure, with a low percentage of severe complications when performed by experienced surgeons. The patients should receive lifetime follow-up. These patients need lifetime follow-up to monitor for potential complications and to facilitate their care if complications occur.

JAMA Otolaryngol Head Neck Surg. 2015;141(11):1012-1017. doi:10.1001/jamaoto.2015.2154
Published online October 15, 2015.

Author Affiliations: Department of Otorhinolaryngology, Louisiana State University Health Science Center, New Orleans (Terry, Jeyakumar); a resident at Louisiana State University Health Science Center, New Orleans (Kelt); now with Department of Pediatrics, The University of Texas Health Science Center, Houston (Kelt).

Corresponding Author: Anita Jeyakumar, MD, MS, Department of Otorhinolaryngology, Louisiana State University Health Science Center, 533 Bolivar St, Ste 566, New Orleans, LA 70112 (ajeyak@lsuhsc.edu).

Cochlear implantation (CI) has been used successfully in the management of severe to profound sensorineural hearing loss in children and adults. In experienced hands, a CI surgery is considered a relatively safe procedure, and several large studies¹⁻³ have published low rates of intraoperative and postoperative complications. Long-term complications, however, are less well defined. The rates of second CIs and long-term complications can have a direct economic impact.⁴ Studies⁵ have reported device malfunction, scalp infection, and device extrusion as the most common long-term complications. At least 1 article⁶ has defined criteria for unification of complications and reporting to allow enhanced review of these studies. Because the number of CI procedures has increased dramatically in the past decade, physicians and patients must be aware of the long-term potential consequences of

the surgery.^{4,7} In this report, we sought to study delayed complications after CI and to review the medical and/or surgical management plans after complications occur.

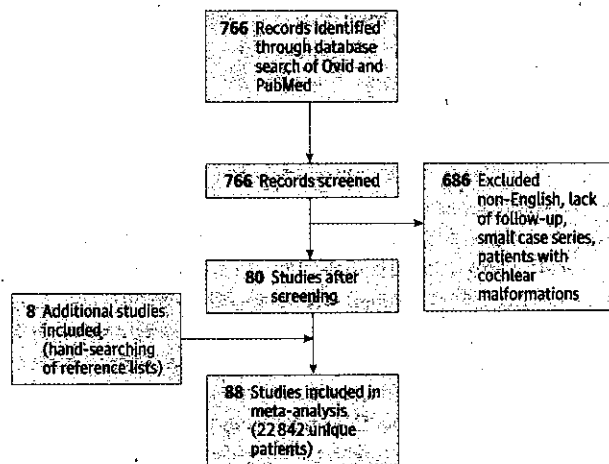
Methods

We performed a systematic review of the literature published from January 1, 2003, through December 31, 2013, for patients who had complications after CI. Searches of the PubMed and OVID databases used the terms *cochlear implant and complications*. The initial search resulted in 766 articles. Studies were included if they reported delayed complications, which were defined as occurring more than 3 days postoperatively. Exclusion criteria consisted of a

8
Adc
88:
Tab
Cor
Vee
Dev
Tas
Ski
Ma
Ele
Sep
Dev
Rec
Dev
Cho
Pac
Mer
Tym
Chix
CSE

language other than English, no record of long-term follow-up, and no report of delayed complications. We also excluded small case series with fewer than 10 patients and series that primarily studied CI in patients with cochlear malformations. We reviewed 80 articles for the study. A PRISMA flow diagram to reflect the selection of these articles is shown in the Figure. Additional articles were added with specific search criteria consisting of *cochlear implant* combined with *mastoiditis*, *meningitis complication*, *otitis media*, *hematoma*, *cholesteatoma*, and *facial nerve injury*. Other articles that were commonly cross-referenced by studies in this review were added. We included a total of 88 articles for analysis during the study period. Data were collected from January 1 through April 1, 2014, and analyzed from April 30 through May 1, 2014.

Figure. PRISMA Flow Diagram



Additional articles were included after the database search for a total of 88 available articles for analysis.

Results

Of the initial 766 identified articles, we reviewed 88 for the study, producing a total of 22,842 unique patients. When reported (in 8519 patients), 4319 patients (50.7%) were male. The patients' ages ranged from 0.2 to 94.9 years, with a mean age of 19.0 years. The duration of follow-up ranged from 1 month to 17 years. The Table summarizes all of the identified complications by adult and pediatric categories.

Vestibular Complications

Fifteen articles^{4,6-19} reviewed vestibular complications in 181 of 4655 patients, for an overall complication rate of 3.9%. Although several studies documented some vestibular concerns, few series provided detailed discussions. Chen et al⁸ reviewed 445 patients older than 60 years who underwent CI from 1999 through 2011. The most common complication observed in their study consisted of balance problems in 30 patients (6.7%), most of whom experienced this complication for longer than 1 month. The balance problems were noted to be more prevalent in adults older than 75 years. Wagner et al⁹ studied vestibular function in a small group of patients with CI (n = 20) using the Dizziness Handicap Inventory, caloric irrigation to test the vestibulo-ocular reflex, and vestibular evoked myogenic potential to test saccular dysfunction. The Dizziness Handicap Inventory showed a moderate but nonsignificant increase in the score after one CI and a significant increase in the score after the second CI. The vestibular evoked myogenic potential responses disappeared in 3 ears after the first CI and in 2 ears after the second CI. The vestibuloocular reflex disappeared in 1 ear only after the first cochlear implant.⁹ Migirov et al¹⁰ reviewed CI in 300 recipients and noted that the incidence of vestibular problems was similar in the adult and pediatric populations.

Taste

Only 5 articles^{6,9,11,19,20} discussed 22 patients with taste complications among 776 CI recipients (2.8%). The largest number of taste

Table. Delayed Complications of Cochlear Implantation

Complication	Total No. of Patients	No. of Complications			Total Incidence, %
		Adult	Pediatric	All ^a	
Vestibular concerns	4655	128	53	181	3.9
Device failure	14,704	136	279	507	3.4
Taste problems	776	16	0	22	2.8
Skin infections	17,878	45	139	238	1.3
Mastoiditis	2996	1	40	42	1.4
Electrode issues	1741	17	12	33	1.9
Sarcoma or teratoma	5486	0	35	48	0.9
Device rejection	1664	1	8	16	1.0
Recurrent otitis	7541	13	39	60	0.8
Device migration	8807	16	32	62	0.7
Cholesteatoma	8579	13	24	40	0.5
Facial nerve weakness	4785	11	8	31	0.6
Meningitis	5234	1	8	9	0.2
Tympanic membrane perforation	557	0	3	3	0.5
Chronic headaches	450	0	4	4	0.9
CSF otorrhea	1979	1	5	6	0.3

Abbreviation: CSF, cerebrospinal fluid

^a Several studies did not delineate adult vs pediatric patients in their data; totals may not represent the combined numbers of pediatric and adult patients.

complications was described by Ikeya et al¹¹ in a review that included 366 patients. However, besides mentioning that 12 adult patients had postoperative taste issues, specific problems and their management were not described. Wagner et al⁹ specifically reviewed taste complaints as well as vestibular complications in 20 patients. Their study reported a subjective feeling of taste dysfunction in 4 patients, including 3 patients after the second CI. However, only 1 patient had objective findings on results of taste testing.⁹

Device Failure

Our study showed that device failure is the second most common complication encountered in patients with CIs. A total of 37 articles^{2-6,8,11,12,16,17,19-45} discussed device failure in 507 of 14 704 patients (3.4%). A large study by Cullen et al²¹ described 952 pediatric patients at 2 large institutions during a 15-year period and found 49 hard failures (uncommon sudden loss of device function) and 16 soft failures (uncommon device malfunction that is very difficult to detect with current software). Sixty-six of their patients (6.9%) required revision surgery with reimplantation. Twenty of their pediatric patients had a history of head trauma. Although not surprising, device failure is cause for concern because of the potential for decreased performance among CI recipients. Failure of the CI device is of particular concern in children because they may not be able to articulate problems with the device. A patient with a suspected device failure often undergoes clinical, audiologic, and radiographic workups in addition to device testing. Unfortunately, many of the patients will present with normal results of device integrity testing.⁴⁶ In fact, the data suggest that, in approximately 50% of cases with suspected device failure, the implants function within the manufacturer's specifications and return normal results of integrity testing, but the devices do not undergo correlation with explanted (ex vivo) device analysis.²² Essentially, the diagnosis is supported by the return of function with the subsequent reimplantation.²³ Once explanted, all devices are sent to the manufacturer for ex vivo device analysis. Most causes of device failure involve fracture of the casing and loss of the hermetic seal.^{22,24}

Skin Infections

We found 11 articles^{5,21,25,26,42-44,47-50} that reported 238 skin infections among 17 878 patients undergoing CI (1.3%). Minor skin infections are more common in the immediate postoperative period. Loundon et al⁴⁷ described skin issues in 23 of 434 patients (5.3%) in a retrospective review performed at a tertiary center. Only 15 patients in their study required revision surgery, with 11 patients needing reimplantation of the device. For patients who required reimplantation, the delay to initial CI ranged from 1.5 months to 7 years. Ray et al²⁵ investigated complications of surgical procedures with different incision lengths. Implants in their study before 1994 used a large incision and had a 2.4% incidence of skin infections; patients with smaller incisions after 1994 had a 1.1% incidence of skin infections. This study showed a small, statistically insignificant decrease in postoperative infections when smaller incisions were used. A similar study by Cullen et al²¹ reviewed 922 pediatric patients undergoing CI and reported a 2.1% rate of skin infection that required surgical intervention in their patient population. Six patients had single surgical procedures, whereas 5 patients underwent multiple

procedures for a total of 16 procedures. Two patients subsequently needed explantation, with revision CI surgery performed in the contralateral ear.²¹

Mastoiditis

Ten articles^{10,17,20,31,41,43,51-54} discussed 42 cases of delayed mastoiditis in a total of 2996 patients undergoing CI (1.4%). The largest study in this review was performed by Osborn et al.⁵¹ The investigators followed up 806 pediatric patients with CI and reported 8 episodes of mastoiditis. All patients were treated with surgical intervention with myringotomy, and 2 patients received postauricular and intravenous antibiotics. The CI was preserved in these cases. Brito et al⁵² reviewed findings in 550 patients (341 children and 209 adults) and found 6 patients with otomastoiditis. Five patients were children, all of whom were successfully treated with admission, intravenous antibiotics, and myringotomy with tubes. The single adult was treated similarly but developed a persistent perforation followed by cholesteatoma formation.

Recurrent Otitis

Fifteen articles* were identified that discussed 60 cases of delayed otitis media in 7541 patients undergoing CI (0.8%). Venail et al⁴ described 5 patients with otitis media among 500 CI recipients. Two of these patients required surgical treatment, and the other 3 were treated with oral antibiotics; none required device removal. Loundon et al⁴⁷ had 4 delayed complications of otitis media among 434 patients. Two patients were treated only with antibiotics and 2 patients required ventilation tubes. Ikeya et al¹¹ performed a review that included 406 patients, among whom were found 13 cases of otitis media. Postoperative otitis media was attributed to wound or flap infections, and 12 patients subsequently required reimplantation. Seven patients were adults with a history of otitis media; 5 patients were children without any history of otitis media. *Staphylococcus aureus* was detected in 6 patients; methicillin-resistant *S aureus*, in 3 patients; and *Aspergillus* species, in 1 patient. Species were unknown in 2 patients. The infections occurred from 1 month to 20 years postoperatively.¹¹

Seroma or Hematoma

Twelve articles† were reviewed that included 5486 patients undergoing CI with 48 (0.9%) delayed complications related to seroma or hematoma. Loundon et al⁴⁷ described 18 pediatric patients with skin issues thought to originate from late seromas or hematomas of unclear origins. Only 15 patients required revision surgery, whereas 3 patients were treated with local wound care. The late occurrence of symptoms was attributed to the children having thinner skin and bone tissue, leading to a tendency to be prone to soft-tissue trauma and subsequent infections.⁴⁷ The incidence of delayed seroma or hematoma complications in the adult population appeared to be very low.⁵⁹

Device Migration

We identified 14 articles‡ that included device migration in 62 of 8807 patients undergoing CI (0.7%). Device migration complications range from asymptomatic occurrences to a requirement of re-

*References 2, 4, 10, 11, 15, 26, 40, 44, 47, 48, 50, 55-58

†References 7, 10, 15, 26, 29, 32, 37, 47, 50, 56, 59, 60

‡References 2, 6, 10, 11, 22, 26, 30, 32, 37, 38, 42, 47, 61, 62

vision surgery for explantation. Black⁶² reported device migration in 6 of 547 cases (1.1%), believing the main cause to be creation of an overly large perichondrial pocket. Methods to secure the device adequately include creation of a smaller or tighter perichondrial pocket, a bony well for stabilization, or suture of the device to bone.

Electrode Issues

We reviewed 10 studies^{6,7,11,19,34,45,63-66} with a total of 1741 patients undergoing CI in whom 33 (1.9%) had electrode array issues that led to explantation. Based on the reports, electrode issues included individual electrode failure, electrode migration, electrodes slipping out, nonauditory stimulation, and electrode exposure. Ikeya et al¹¹ described 4 patients with electrode problems, all of whom had to undergo reimplantation. Carlson et al⁶³ found that 9.0% of all CIs showed at least 1 individual electrode that failed. Schow et al⁶⁴ demonstrated that, of 322 implanted devices, the overall explantation rate was 6.1% and the individual electrode failure rate was 6.8%; however, individual electrode failure led to only 3 explantations (0.9% of patients). One individual electrode that does not function in an array does not cause noticeable effects, but cumulative malfunction of electrodes can cause a decrease in the hearing benefit.^{63,64} Older studies have reported a higher incidence of electrode problems, including an incidence of 4.3% in 4969 patients⁶⁵ and an incidence of 6.5% in 153 patients.⁶⁶

Cholesteatoma

A total of 16 articles[§] reviewed found postoperative cholesteatoma in 40 of 8579 patients undergoing CI (0.5%). Brito et al⁵² described 6 patients with postoperative cholesteatoma that developed at 18 to 84 months after surgery, and all patients required subsequent operative interventions. The mean time to cholesteatoma development was 45 months, which was consistent with the findings of other studies. The late onset of these complications demonstrates the need for extended follow-up after CI.⁶⁷

Facial Nerve Weakness

We reviewed a total of 18 articles^{||} with a postoperative incidence of delayed facial nerve weakness in 31 of 4785 patients undergoing CI (0.6%). Postoperative facial nerve weakness is rare but can occur within 2 days in association with edema or nerve injury or can be delayed after 3 days, for which a few theories have been formed. The reactivation of herpesvirus affecting the facial nerve function is well documented after tympanomastoid surgery, including CI.⁵⁵ Surgical procedures with extensive nerve manipulation, such as trigeminal rhizotomy, are associated with high viral reactivation.⁶⁸ Sources of nerve manipulation could occur with the creation of a tympanomeatal flap, but a more reasonable source is manipulation or transection of the chorda tympani.⁶⁹ Chen et al⁸ reported 2 patients with transient delayed weakness of the facial nerve; both patients had full return of function. Thom et al⁷⁰ reviewed findings in 888 patients (282 children and 606 adults) and described 10 patients with delayed facial nerve paresis. All the patients had complete resolution of their symptoms, and treatment with corticosteroids was recommended for any patient with delayed postoperative facial nerve weakness.⁷⁰ Joseph et al⁷¹ performed an extensive literature review for patients with delayed facial nerve paresis after

§References 2-4, 6, 7, 10, 14, 21, 31, 38, 41, 42, 47, 52, 56, 67

|| References 6-8, 10, 15, 20, 28, 38, 52, 53, 55, 60, 68-73

CI. The study postulated the mechanisms for paresis to be neural edema, vasospasm, and viral reactivation. The investigators recommended assessment of viral titers and treatment with corticosteroids, antivirals, and physiotherapy for faster resolution of symptoms. The data did not show a significant difference in incidence between the pediatric and adult populations.

Meningitis

We reviewed 18 studies[#] with a total of 5324 patients undergoing CI, among whom 9 cases (0.2%) of meningitis were identified. Historically, a landmark study initiated by the Centers for Disease Control and Prevention by Reefhuis et al⁷⁵ and conducted from January 1997 to August 2002 showed 21 total cases of delayed meningitis among 4265 patients (before our study period). Those investigators found a significant increase in meningitis after 30 days of 1060.3 vs 53.3 cases per 100 000 person-years associated with implants using a positioner vs no positioner. The manufacturer initiated a voluntary recall of the devices in July 2002. Our data suggest a significant decrease in the incidence of meningitis after recall of the positioner. Considerations to reduce cases of meningitis in patients undergoing CI include aggressive treatment of acute otitis media and mastoiditis.^{75,76} In addition, the Centers for Disease Control and Prevention has specific vaccine guidelines for implant recipients before and after CI.

Device Rejection and Extrusion

We found 8 studies^{5,10,19,22,28,37,74,77} with 1664 patients undergoing CI in which 16 cases (1.0%) of device rejection or extrusion were noted. Pirzadeh et al⁷⁷ reported 6 cases of device rejection. All cases had a cholesteatoma and a granular reaction up to 9 months after surgery. Possible contributing factors in that study included wearing a hat, previous mastoid surgery, and a previous scar.⁷⁷ Migirov et al¹⁰ described 2 children who required explantation after a foreign body reaction. Histologic findings were consistent with giant-cell reaction to foreign bodies. Reimplantation was successful with an electrode from another company for 1 patient.⁷⁷ Rivas et al²² discussed the possibility of silicone allergy as a cause of device problems, particularly in cases in which the cultures had normal findings and with no local response to antibiotics. The concept of silicone allergy had been discussed by Kunda et al,⁷⁴ who reviewed 3 cases from 1991 through 2004. Both studies acknowledged that only limited data existed but indicated that all the manufacturers (Cochlear Inc, Med El, and Advanced Bionics) have test kits to check for allergies and that all of them have the ability to make custom devices without silicone or with a ceramic housing for the receiver in patients with known allergies or those who need replacement devices after being diagnosed with allergies.²²

Chronic Headaches

Two studies^{27,53} discussed patients with chronic headaches after CI, with an incidence of 4 cases among 450 patients (0.9%). In both studies reviewed, the cause of the pain was unknown. Kandogan et al²⁷ reported 3 cases of chronic head pain that began after CI and continued sporadically for years after the original surgery. A case reported by Black et al⁵³ described a 5-year-old girl with chronic head pain on the side of the implant 2 years after the procedure. The head-

#References 2, 8, 10, 12, 16, 17, 19, 20, 26, 28, 40, 47, 52, 59, 74-77

ache resolved without explanation, but severe pain to the site 4 years after implantation warranted surgical exploration. At that time, the receiver package had displaced forward from its bed and rested above the ear.

Discussion

Our review focused on delayed complications of CI procedures and is intended to be comprehensive based on the available reported data. However, the review relies on how complications have been reported in the literature, which limits the scope of our findings. We suspect that the complications have been underreported. Several studies focused on particular complications and may not have re-

ported all complications. In addition, some studies did not focus on the demographic information of the populations, making pediatric vs adult data difficult to analyze.

Conclusions

Cochlear implantation continues to be a reliable and safe procedure with a low percentage of severe complications when performed by experienced surgeons. The 3 most common delayed complications found in this study include device failure, skin infections, and vestibular concerns. Although the incidence of complications is low, the possibility of long-term complications warrants lifetime follow-up for the patient.

ARTICLE INFORMATION

Submitted for Publication: February 11, 2015; final revision received July 2, 2015; accepted August 12, 2015.

Published Online: October 15, 2015.
doi:10.1001/jamaoto.2015.2154.

Author Contributions: Drs Jeyakumar and Terry had full access to all the data in the study and take responsibility for the integrity of the data and the accuracy of the data analysis.

Study concept and design: All authors.

Acquisition, analysis, or interpretation of data: All authors.

Drafting of the manuscript: Terry.

Critical revision of the manuscript for important intellectual content: All authors.

Statistical analysis: Terry, Jeyakumar.

Administrative, technical, or material support: Terry, Jeyakumar.

Study supervision: Jeyakumar.

Conflict of Interest Disclosures: None reported.

Previous Presentation: This study was presented in part at the 117th Annual Meeting of the Triologic Combined Otolaryngology Spring Meetings; May 16, 2014; Las Vegas, Nevada.

REFERENCES

- Fayad JN, Bains T, Parisier SC. Revision cochlear implant surgery: causes and outcome. *Otolaryngol Head Neck Surg.* 2004;131(4):429-432.
- Côté M, Ferron P, Bergeron F, Bussièrès R. Cochlear reimplantation: causes of failure, outcomes, and audiologic performance. *Laryngoscope.* 2007;117(7):1225-1235.
- Lassig AA, Zwolan TA, Telian SA. Cochlear implant failures and revision. *Otol Neurotol.* 2005;26(4):624-634.
- Venail F, Sicard M, Piron JP, et al. Reliability and complications of 500 consecutive cochlear implantations. *Arch Otolaryngol Head Neck Surg.* 2008;134(12):1276-1281.
- Stamatiou GA, Kyrodimos E, Sismanis A. Complications of cochlear implantation in adults. *Ann Otol Rhinol Laryngol.* 2011;120(7):428-432.
- Jeppesen J, Faber CE. Surgical complications following cochlear implantation in adults based on a proposed reporting consensus. *Acta Otolaryngol.* 2013;133(10):1012-1021.
- Hansen S, Anthonen K, Stangerup SE, Jensen JH, Thomsen J, Cayé-Thomasen P. Unexpected findings and surgical complications in 505 consecutive cochlear implantations: a proposal for reporting consensus. *Acta Otolaryngol.* 2010;130(5):540-549.
- Chen DS, Clarrett DM, Li L, Bowditch SP, Niparko JK, Lin FR. Cochlear implantation in older adults: long-term analysis of complications and device survival in a consecutive series. *Otol Neurotol.* 2013;34(7):1272-1277.
- Wagner JH, Basta D, Wagner F, Seidl RO, Ernst A, Todt I. Vestibular and taste disorders after bilateral cochlear implantation. *Eur Arch Otorhinolaryngol.* 2010;267(12):1849-1854.
- Migirov L, Muchnik C, Kaplan-Neeman R, Kronenberg J. Surgical and medical complications in paediatric cochlear implantation: a review of 300 cases. *Cochlear Implants Int.* 2006;7(4):194-201.
- Ikeya J, Kawano A, Nishiyama N, Kawaguchi S, Hagiwara A, Suzuki M. Long-term complications after cochlear implantation. *Auris Nasus Larynx.* 2013;40(6):525-529.
- Ciorba A, Bovo R, Trevisi P, et al. Postoperative complications in cochlear implants: a retrospective analysis of 438 consecutive cases. *Eur Arch Otorhinolaryngol.* 2012;269(6):1599-1603.
- Yin S, Chen Z, Wu Y, et al. Suprameatal approach for cochlear implantation in 45 Chinese children. *Int J Pediatr Otorhinolaryngol.* 2008;72(3):397-403.
- Migirov L, Dagan E, Kronenberg J. Surgical and medical complications in different cochlear implant devices. *Acta Otolaryngol.* 2009;129(7):741-744.
- Postelmans JT, Cleffken B, Stokroos RJ. Post-operative complications of cochlear implantation in adults and children: five years' experience in Maastricht. *J Laryngol Otol.* 2007;121(4):318-323.
- Ajallouyeen M, Amirsalari S, Yousefi J, Raeesi MA, Radfar S, Hassanalifard M. A report of surgical complications in a series of 262 consecutive pediatric cochlear implantations in Iran. *Iran J Pediatr.* 2011;21(4):455-460.
- Johnston JC, Smith AD, Fitzpatrick E, et al. Estimation of risks associated with paediatric cochlear implantation. *Cochlear Implants Int.* 2010;11(3):146-169.
- Shoman N, Ngo R, Archibald J, Pijl S, Chan S, Westerberg BD. Prevalence of new-onset vestibular symptoms following cochlear implantation. *J Otolaryngol Head Neck Surg.* 2008;37(3):388-394.
- Green KM, Bhatt YM, Saeed SR, Ramsden RT. Complications following adult cochlear implantation: experience in Manchester. *J Laryngol Otol.* 2004;118(6):417-420.
- Stratigouleas ED, Perry BP, King SM, Syms CA III. Complication rate of minimally invasive cochlear implantation. *Otolaryngol Head Neck Surg.* 2006;135(3):383-386.
- Cullen RD, Fayad JN, Luxford WM, Buchman CA. Revision cochlear implant surgery in children. *Otol Neurotol.* 2008;29(2):214-220.
- Rivas A, Marlowe AL, Chinnici JE, Niparko JK, Francis HW. Revision cochlear implantation surgery in adults: indications and results. *Otol Neurotol.* 2008;29(5):639-648.
- Balkany TJ, Hodges AV, Buchman CA, et al. Cochlear implant Soft Failures Consensus Development Conference statement. *Otol Neurotol.* 2005;26(4):815-818.
- Brown KD, Connell SS, Balkany TJ, Eshraghi AE, Telischi FF, Angeli SA. Incidence and indications for revision cochlear implant surgery in adults and children. *Laryngoscope.* 2009;119(1):152-157.
- Ray J, Gibson W, Sanli H. Surgical complications of 844 consecutive cochlear implantations and observations on large versus small incisions. *Cochlear Implants Int.* 2004;5(3):87-95.
- Tarkan Ö, Tuncer Ö, Özdemir S, et al. Surgical and medical management for complications in 475 consecutive pediatric cochlear implantations. *Int J Pediatr Otorhinolaryngol.* 2013;77(4):473-479.
- Kandogan T, Levent O, Gurol G. Complications of paediatric cochlear implantation: experience in Izmir. *J Laryngol Otol.* 2005;119(8):606-610.
- Qiu J, Chen Y, Tan P, et al. Complications and clinical analysis of 416 consecutive cochlear implantations. *Int J Pediatr Otorhinolaryngol.* 2011;75(9):1143-1146.
- Davidts T, Ramsden JD, Gordon KA, James AL, Papsin BC. Soft tissue complications after small incision pediatric cochlear implantation. *Laryngoscope.* 2009;119(5):980-983.
- McJunkin J, Jeyakumar A. Complications in pediatric cochlear implants. *Am J Otolaryngol.* 2010;31(2):110-113.
- Lescanne E, Al Zahrani M, Bakhos D, Robier A, Morinière S. Revision surgeries and medical interventions in young cochlear implant recipients. *Int J Pediatr Otorhinolaryngol.* 2011;75(10):1221-1224.

32. Roland JT Jr, Cosetti M, Wang KH, Immerman S, Waltzman SB. Cochlear implantation in the very young child: long-term safety and efficacy. *Laryngoscope*. 2009;119(11):2205-2210.
33. Postelmans JTF, Tange RA, Stokroos RJ, Grolman W. The suprameatal approach: a safe alternative surgical technique for cochlear implantation. *Otol Neurotol*. 2010;31(2):196-203.
34. Lima LRP Jr, Rodrigues FA Jr, Calhau CM, Calhau AC, Palhano CT. Postoperative complications in implanted patients in the Cochlear Implant Program of Rio Grande do Norte-Brazil [in Portuguese]. *Brazilian J Otorhinolaryngol*. 2010;76(4):517-521.
35. Velegrakis GA, Karatzanis AD, Prokopakis EP, et al. The cochlear implant programme in Crete: a nine year experience. *Cochlear Implants Int*. 2008;9(4):215-222.
36. Hopfenspirger MT, Levine SC, Rimell FL. Infectious complications in pediatric cochlear implants. *Laryngoscope*. 2007;117(10):1825-1829.
37. Dodson KM, Maiberger PG, Sismanis A. Intracranial complications of cochlear implantation. *Otol Neurotol*. 2007;28(4):459-462.
38. Arnoldner C, Baumgartner WD, Gstoettner W, Hamzavi J. Surgical considerations in cochlear implantation in children and adults: a review of 342 cases in Vienna. *Acta Otolaryngol*. 2005;125(3):228-234.
39. Valencia DM, Rimell FL, Friedman BJ, Oblander MR, Helmbrecht J. Cochlear implantation in infants less than 12 months of age. *Int J Pediatr Otorhinolaryngol*. 2008;72(6):767-773.
40. Ahn JH, Chung JW, Lee KS. Complications following cochlear implantation in patients with anomalous inner ears: experiences in Asan Medical Center. *Acta Otolaryngol*. 2008;128(1):38-42.
41. Postelmans JTF, Stokroos RJ, Linmans JJ, Kremer B. Cochlear implantation in patients with chronic otitis media: 7 years' experience in Maastricht. *Eur Arch Otorhinolaryngol*. 2009;266(8):1159-1165.
42. Migrov L, Taitelbaum-Swead R, Hildesheimer M, Kronenberg J. Revision surgeries in cochlear implant patients: a review of 45 cases. *Eur Arch Otorhinolaryngol*. 2007;264(1):3-7.
43. Postelmans JTF, Grolman W, Tange RA, Stokroos RJ. Comparison of two approaches to the surgical management of cochlear implantation. *Laryngoscope*. 2009;119(8):1571-1578.
44. Masterson L, Kumar S, Kong JHK, et al. Cochlear implant failures: lessons learned from a UK centre. *J Laryngol Otol*. 2012;126(1):15-21.
45. Dutt SN, Ray J, Hadjihannas E, Cooper H, Donaldson I, Proops DW. Medical and surgical complications of the second 100 adult cochlear implant patients in Birmingham. *J Laryngol Otol*. 2005;119(10):759-764.
46. Marlowe AL, Chinnici JE, Rivas A, Niparko JK, Francis HW. Revision cochlear implant surgery in children: the Johns Hopkins experience. *Otol Neurotol*. 2010;31(1):74-82.
47. Loundon N, Blanchard M, Roger G, Denoyelle F, Garabedian EN. Medical and surgical complications in pediatric cochlear implantation. *Arch Otolaryngol Head Neck Surg*. 2010;136(1):12-15.
48. Ramsden JD, Papsin BC, Leung R, James A, Gordon KA. Bilateral simultaneous cochlear implantation in children: our first 50 cases. *Laryngoscope*. 2009;119(12):2444-2448.
49. Kabelka Z, Groh D, Katra R, Jurovcik M. Bacterial infection complications in children with cochlear implants in the Czech Republic. *Int J Pediatr Otorhinolaryngol*. 2010;74(5):499-502.
50. Shelton C, Warren FM. Minimal access cochlear implant fixation: temporalis pocket with a plate. *Otol Neurotol*. 2012;33(9):1530-1534.
51. Osborn HA, Cushing SL, Gordon KA, James AL, Papsin BC. The management of acute mastoiditis in children with cochlear implants: saving the device. *Cochlear Implants Int*. 2013;14(5):252-256.
52. Brito R, Monteiro TA, Leal AF, Tsuji RK, Pinna MH, Bento RF. Surgical complications in 550 consecutive cochlear implantation. *Braz J Otorhinolaryngol*. 2012;78(3):80-85.
53. Black IM, Bailey CM, Albert DM, et al. The Great Ormond Street Hospital paediatric cochlear implant programme 1992-2004: a review of surgical complications. *Cochlear Implants Int*. 2007;8(2):53-67.
54. Migrov L, Taitelbaum-Swead R, Drendel M, Hildesheimer M, Kronenberg J. Cochlear implantation in elderly patients: surgical and audiological outcome. *Gerontology*. 2010;56(2):123-128.
55. Nabors MW, Francis CK, Kobrine AI. Reactivation of herpesvirus in neurosurgical patients. *Neurosurgery*. 1986;19(4):599-603.
56. Bhatia K, Gibbin KP, Nikolopoulos TP, O'Donoghue GM. Surgical complications and their management in a series of 300 consecutive pediatric cochlear implantations. *Otol Neurotol*. 2004;25(5):730-739.
57. Bajaj Y, Wyatt M, Hartley B. Small postaural incision for paediatric cochlear implantation. *Cochlear Implants Int*. 2005;6(2):77-84.
58. Sorrentino T, Coté M, Eter E, et al. Cochlear reimplantations: technical and surgical failures. *Acta Otolaryngol*. 2009;129(4):380-384.
59. Ovesen T, Johansen LV. Post-operative problems and complications in 313 consecutive cochlear implantations. *J Laryngol Otol*. 2009;123(5):492-496.
60. Kim CS, Oh SH, Chang SO, Kim HM, Hur DG. Management of complications in cochlear implantation. *Acta Otolaryngol*. 2008;128(4):408-414.
61. Al-Muhaimeed HS, Al-Anazy F, Attallah MS, Hamed O. Cochlear implantation at King Abdulaziz University Hospital, Riyadh, Saudi Arabia: a 12-year experience. *J Laryngol Otol*. 2009;123(11):e20.
62. Black B. Keyhole cochlear implantation: current status. *Otol Neurotol*. 2011;32(9):1459-1463.
63. Carlson ML, Archibald DJ, Dabade TS, et al. Prevalence and timing of individual cochlear implant electrode failures. *Otol Neurotol*. 2010;31(6):893-898.
64. Schow B, Friedland DR, Jensen J, Burg L, Runge CL. Electrode failure and device failure in adult cochlear implantation. *Cochlear Implants Int*. 2012;13(1):35-40.
65. Webb RL, Lehnhardt E, Clark GM, Laszig R, Pyman BC, Franz BK. Surgical complications with the cochlear multiple-channel intracochlear implant: experience at Hannover and Melbourne. *Ann Otol Rhinol Laryngol*. 1991;100(2):131-136.
66. Hoffman RA, Cohen NL. Complications of cochlear implant surgery. *Ann Otol Rhinol Laryngol Suppl*. 1995;166:420-422.
67. Bibas A, Phillips S, Bailey CM, Papsin BC. Chronic suppurative otitis media following paediatric cochlear implantation. *Cochlear Implants Int*. 2006;7(3):167-178.
68. Grimm RJ. Activation of latent herpesvirus type I by trigeminal rhizotomy: a hypothesis. *Trans Am Neurol Assoc*. 1973;98:170-174.
69. Shea JJ Jr, Ge X. Delayed facial palsy after stapedectomy. *Otol Neurotol*. 2001;22(4):465-470.
70. Thom JJ, Carlson ML, Olson MD, et al. The prevalence and clinical course of facial nerve paresis following cochlear implant surgery. *Laryngoscope*. 2013;123(4):1000-1004.
71. Joseph ST, Vishwakarma R, Ramani MK, Aurora R. Cochlear implant and delayed facial palsy. *Cochlear Implants Int*. 2009;10(4):229-236.
72. Eshraghi AA, Rodriguez M, Balkany TJ, et al. Cochlear implant surgery in patients more than seventy-nine years old. *Laryngoscope*. 2009;119(6):1180-1183.
73. Kyriafinis G, Vital V, Psifidis A, et al. Preoperative evaluation, surgical procedure, follow up and results of 150 cochlear implantations. *Hippokratia*. 2007;11(2):77-82.
74. Kunda LD, Stidham KR, Inseerra MM, Roland PS, Franklin D, Roberson JB Jr. Silicone allergy: a new cause for cochlear implant extrusion and its management. *Otol Neurotol*. 2006;27(8):1078-1082.
75. Reefhuis J, Honein MA, Whitney CG, et al. Risk of bacterial meningitis in children with cochlear implants. *N Engl J Med*. 2003;349(5):435-445.
76. Biernath KR, Reefhuis J, Whitney CG, et al. Bacterial meningitis among children with cochlear implants beyond 24 months after implantation. *Pediatrics*. 2006;117(2):284-289.
77. Pirzadeh A, Khorsandi M, Mohammadi MA, Pirzadeh A. Complications related to cochlear implants: experience in Tehran. *J Pak Med Assoc*. 2011;61(7):622-624.